

GUNDERSEN HEALTH SYSTEM ULTRASOUND DEPARTMENT
POLICY AND PROCEDURE MANUAL

SUBJECT: Sonographic Imaging in the Evaluation of Pyloric Stenosis
SECTION: Radiology Ultrasound
ORIGINATOR: Deborah L. Richert, BSVT, RDMS, RVT
REVISED DATE: October 9, 2021

APPROVED BY:

Jody Riherd MD

Kaylee Waldvogel RDMS RVT MBA

Prep: NPO for 3 hours is suggested, however, sonograms can be attempted if the infant has not been NPO for the suggested time frame

Patient Position: Start with the infant in a supine position but may also need to move infant into LT lateral or RT lateral position for better visualization. On some occasions having the parent hold the infant in an upright or semi-upright position may be helpful.

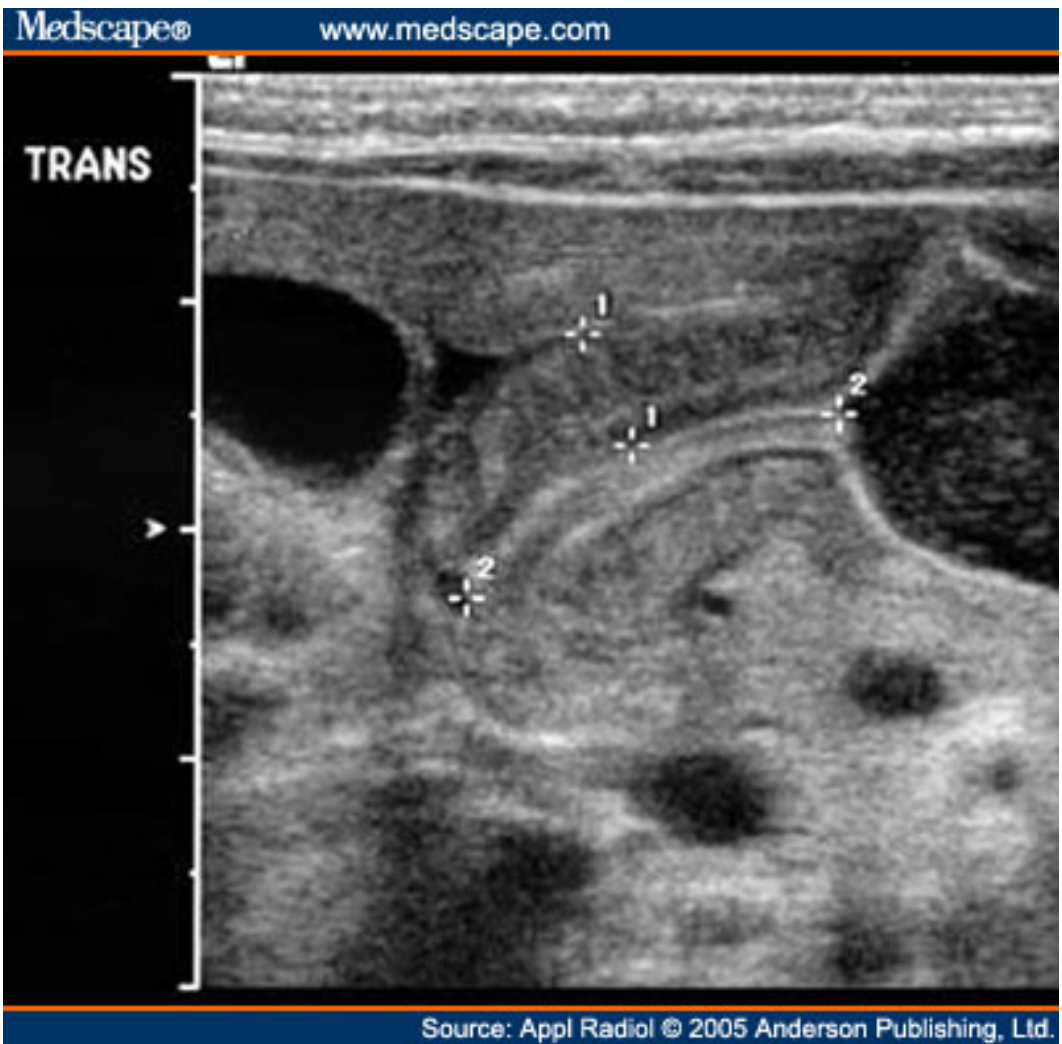
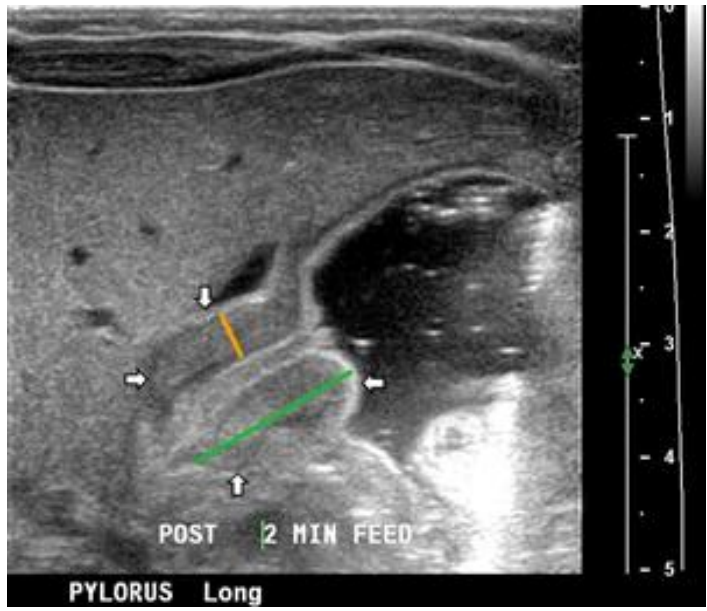
Equipment: The use of a high frequency (9 to 15 MHz) linear transducer is preferred

Imaging Protocol:

THE INFANT SHOULD BE SCANNED FOR AT LEAST 15 MINUTES UNLESS THE EXAM IS OBVIOUSLY NORMAL.

THE 15 MINUTES MAY BE CONTINUOUS OR THE SONOGRAPHER CAN TAKE A BREAK AND SCAN AGAIN AS LONG AS TOTAL IMAGING TIME IS AT LEAST 15 MINUTES (unless obviously normal).

1. 3 transverse images of the pylorus/pyloric area.
2. 3 longitudinal images of the pylorus/pyloric area. If the pylorus is visualized measurements of the muscle thickness (hypoechoic muscle layer) and pyloric channel length should be obtained.
3. 3 cineclips of the pylorus demonstrating movement (or the absence of movement) of fluid from the infant's stomach through the pylorus and into the duodenum. If the stomach is empty, or no fluid is seen traversing the pylorus—give the infant a few ounces of water while imaging the pylorus.



Pyloric stenosis

